

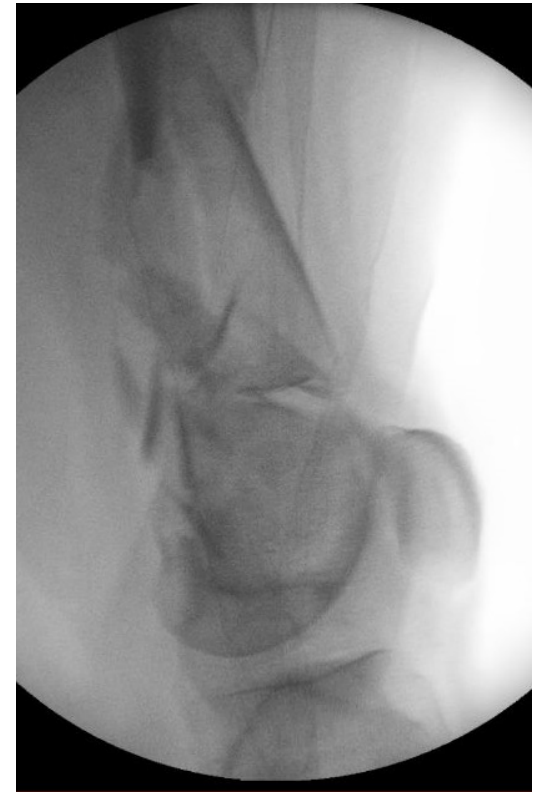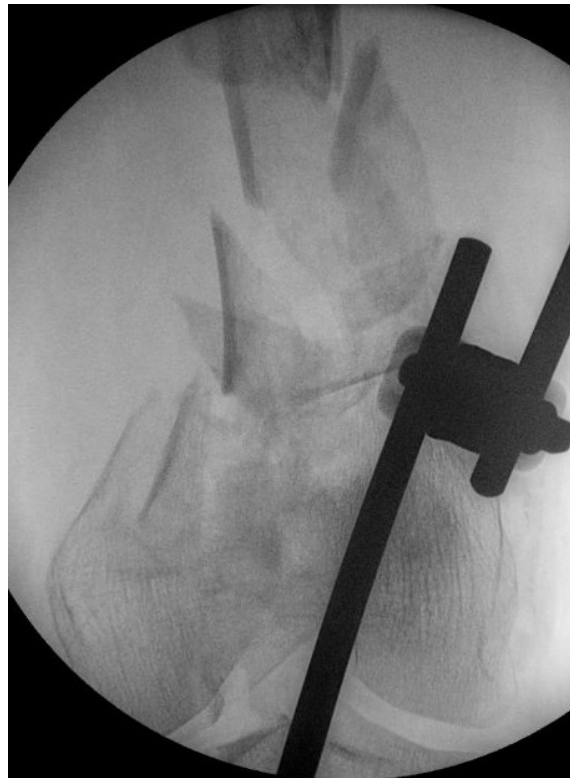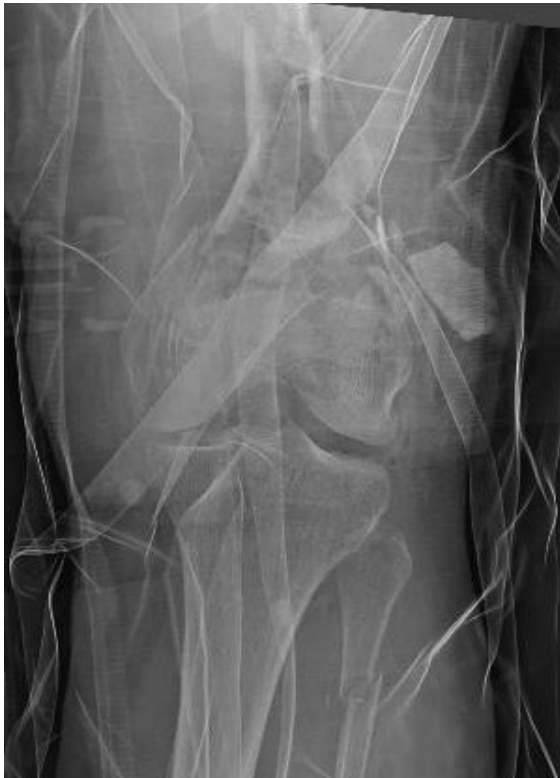# Knee Course Val d'Isère 2024

## Clinical cases

S. Devos, CHU Charleroi, Belgium

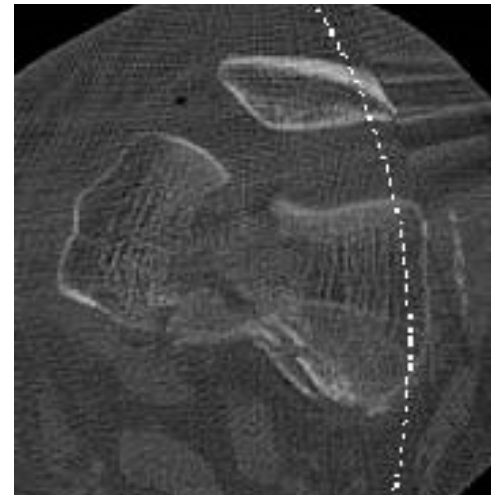
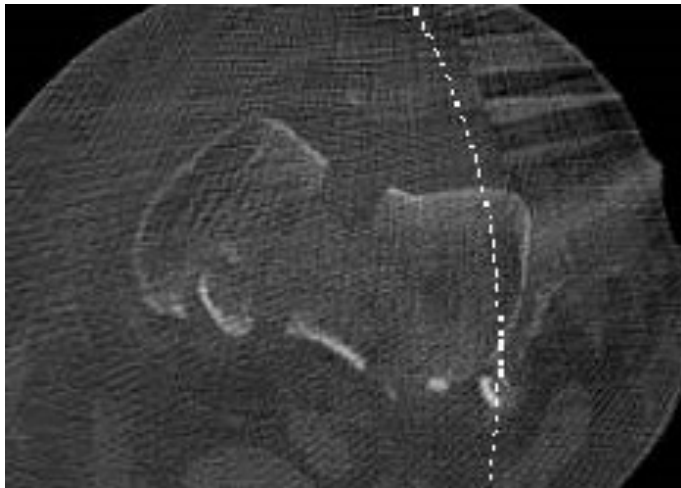
## 60-year old woman, motor vehicle accident, heavy smoker

- open and comminuted inter and supra-condylar fracture of the left distal femur, Gustillo 3a



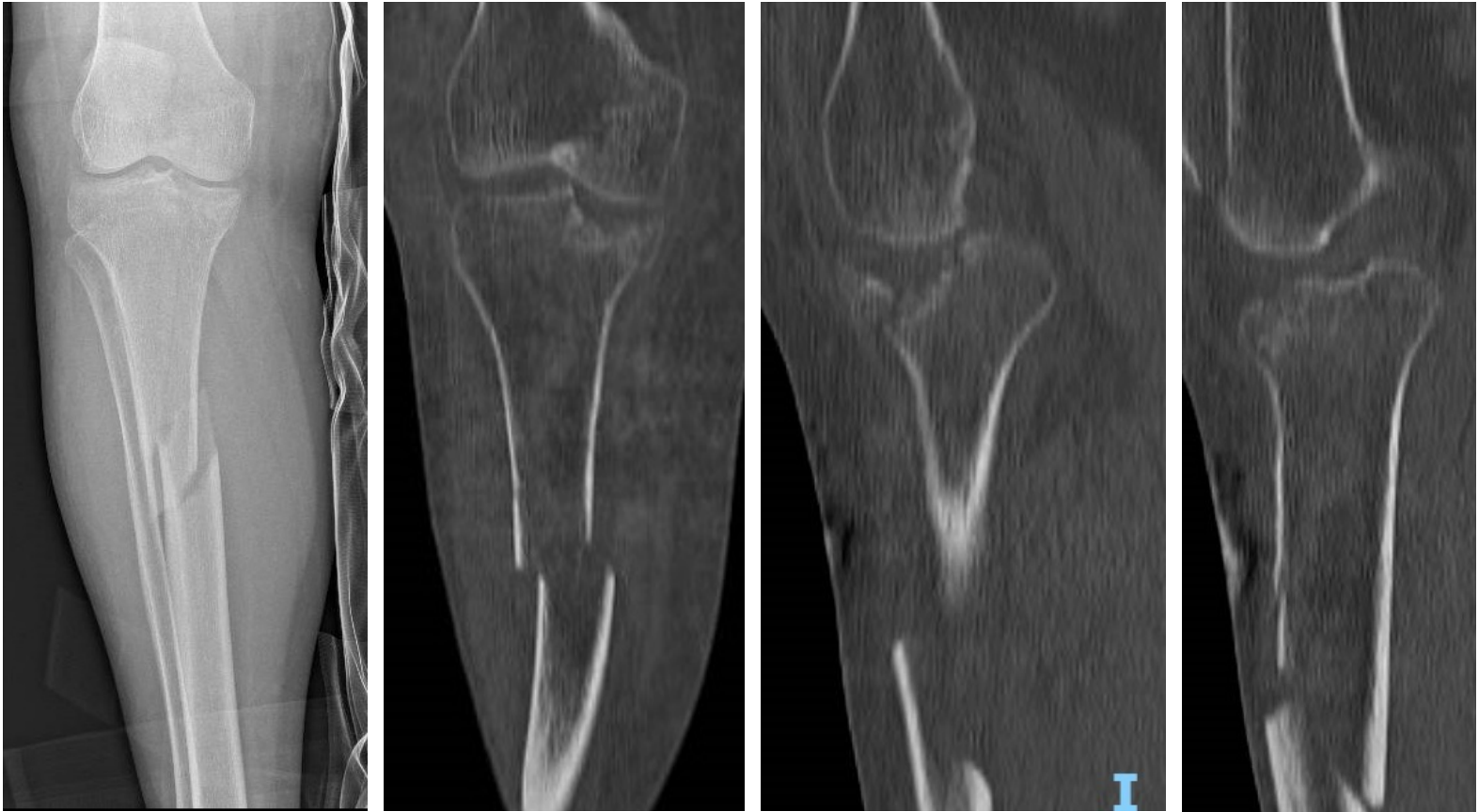
60-year old woman, motor vehicle accident, heavy smoker

- open and comminuted inter and supra-condylar fracture of the left distal femur, Gustillo 3a



60-year old woman, motor vehicle accident, heavy smoker

- closed medial tibial plateau and spinal fracture of the right tibia Schatzker IV
- diaphyseal fracture of the right tibial



## 24-year old man, motor vehicule accident

- Closed proximal tibial plateau fracture Schatzker IV
- Compartment syndrome day 2, fasciotomy and femoro-tibial external fixateur

